



A M E D I C A[®]

TECHNOLOGY UPDATE

Imaging Benefits of Silicon Nitride Spinal Implants

www.amediacorp.com : 1885 West 2100 South, Salt Lake City, UT 84119 : 801.839.3500

Clinicians have identified several key imaging characteristics that affect spinal implant performance.

- Radiolucency: aides evaluation of tissues inside and behind implants
- Radioopacity: aides intraoperative placement and implant evaluation
- CT and MRI compatibility: aides evaluation of soft tissues, especially neural structures

From an imaging standpoint, the ideal implant material would be easy to identify on fluoroscopy, and allow for postoperative evaluation of bony and soft tissue structures using CT and MRI.

To better understand the effect of material on imaging performance, identical cylinders (7mm H x 15.5mm D) were manufactured from the following materials:

METAL

Titanium (Ti), 316L stainless steel (316L), Cobalt chromium steel (CoCr), Porous tantalum (Ta) hemi cylinder

POLYMER

Poly ether ether ketone (PEEK), Ultra high molecular weight polyethylene (UHMWPE)

CERAMIC

Silicon nitride (SiN), Alumina (Al), Zirconia toughened alumina (ZTA), Zirconia (Zr)

The cylinders were tested under identical parameters in the following medical imaging devices. Axial and sagittal images were collected to fully evaluate material performance.






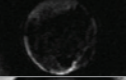


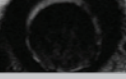





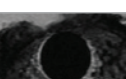


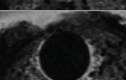




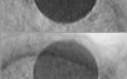
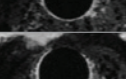

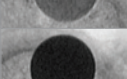
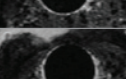


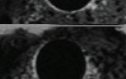
- Fluoroscopy
- Magnetic Resonance Imaging (MRI)
- Computed Tomography (CT)
- Plain Film X-ray

FLUOROSCOPIC AND X-RAY IMAGING

Radiographic and fluoroscopic lucency is heavily influenced by the material, density and thickness of an implant. Polymer implants, including PEEK and UHMWPE, are completely invisible under fluoro and plain film x-ray. This radiolucency can make it difficult to place these implants intraoperatively.

While this lucency may be beneficial for evaluating bony ingress into the implant, it makes it impossible to determine the level of cellular adhesion and skeletal attachment.

AXIAL VIEWPOINT OF DIFFERENT MATERIALS

PRODUCT	FLUOROSCOPIC IMAGING	MRI: Magnetic resonance imaging	CT: Computer Tomography Imaging
METAL			
Titanium (Ti)			
316L Stainless steel (316L)			
Cobalt chromium steel (CoCr)			
Porous tantalum (Ta) hemi cylinder 1			
POLYMER			
Poly ether ether ketone (PEEK)			
Ultra high molecular weight polyethylene (UHMWPE)			
CERAMIC			
Silicon nitride (SiN)			
Alumina (Al)			
Zirconia toughened alumina (ZTA)			
Zirconia (Zr)			



On the other end of the spectrum are radioopaque implants. Dense materials, especially metals like titanium, cobalt chrome steel, stainless steel, and tantalum are completely radioopaque. Histologically, titanium has shown favorable results for cellular and skeletal attachment. However, many doctors have turned to polymer implants because evaluating the ingress of new bone into a metal implant is not possible on plain film x-ray or fluoroscopy.

Ceramics, such as alumina and silicon nitride become more radioopaque as they increase in thickness. The difference in lucency between the sagittal and axial films confirms this relationship. It is possible to evaluate bony ingress into the cage, as well as skeletal attachment and cellular adhesion to the cage itself, as long as wall thickness is kept below a certain level.

MAGNETIC RESONANCE IMAGING (MRI)

MRI is vital for evaluating soft tissue structures in and around the spine—especially neural structures, the intervertebral disc and intravertebral abscesses or tumors. Dense, metallic materials obscure the computer's ability to read an image, resulting in a large "bloom" or imaging artifact that obstructs visualization of surrounding tissue.

This bloom is one of the primary reasons spinal surgeons have moved away from metal implants.

Non-metallic ceramic implants are visible under MRI without creating any artifact.

COMPUTED TOMOGRAPHY IMAGING (CT)

CT scans help doctors evaluate the integrity of bony structures, nucleus pulposa health, and the degree of bony impingement on neural structures. Metal cylinders all exhibit some degree of streaking. These obstructions preclude evaluation of bony attachment at the implant interface.

Silicon nitride does not interfere with surrounding tissue visualization. This clarity aids significantly in evaluation of the bone/implant interface.

CONCLUSION

Metal implants, while demonstrating the potential for excellent cellular and bony adhesion, obscure postoperative evaluation of bony and neural structures in all three imaging modalities.

Polymer based implants, such as PEEK and UHMPE, are invisible on fluoroscopy, aiding in postoperative evaluation of intervertebral activity, but making intraoperative placement difficult.

However, silicon nitride can be manufactured to allow for intraoperative visualization, while also enhancing CT and MRI postoperative evaluation of bony and soft tissue structures. This makes it a preferred material for spinal implant procedures.